

Acute Appendicitis Presenting as Right Upper Quadrant Pain: A Case Report

Sofia Isabel T. Manlubatan, MD²; Jaime Antonio O. Yu, MD¹ and Marc Paul J. Lopez, MD, FPCS²

Appendicitis is one of the most commonly encountered general surgery emergencies worldwide and has been extensively studied. However, anatomical variations in the position of the appendix may result in atypical clinical presentations, leading to diagnostic difficulty and delays in management. Reported here is a case of subhepatic appendicitis in a young adult patient who successfully underwent laparoscopic appendectomy. Subhepatic appendicitis is a rare surgical entity that should be considered in patients presenting with right upper quadrant abdominal pain. Contrast-enhanced computed tomography and laparoscopy are valuable tools in the diagnosis and management of this uncommon condition.

Key words: Acute appendicitis, subhepatic appendicitis, laparoscopic appendectomy

Acute appendicitis is one of the most commonly encountered general surgical emergencies in children and young adults worldwide. The anatomy and embryologic development of the of the appendix, as well as the classical presentation of appendicitis, are well-documented in literature.¹ Typically, patients present with periumbilical pain migrating to the right lower quadrant, accompanied by anorexia, nausea, and leukocytosis.

Aberrations in the position of the appendix, however, may significantly alter this clinical presentation, resulting in diagnosis uncertainty and delays in management. Depending on its location, an inflamed appendix may mimic other pathologies, leading clinicians to pursue alternative diagnoses.

Subhepatic appendicitis is a rare anatomical variant, accounting for approximately 0.08% of all appendicitis

cases. It is a result of midgut malrotation or arrest of cecal descent during embryologic development.^{2,3}

This case is presented to highlight how subhepatic appendicitis, given its rarity and atypical presentation, remains a diagnostic challenge. It can mimic other conditions of the upper abdomen; therefore, a high index of suspicion of these anatomical variants is necessary in the prompt and safe management of such cases.

The Case

A 25-year-old female presented to the emergency department with a two-day history of epigastric pain that migrated to the right upper quadrant. She denied nausea, fever, or loss of appetite. She had no significant past medical history and no previous surgeries. This was her first hospitalization. She came in with a report from a local hospital describing a plain computed tomography (CT) scan that raised suspicion for acute appendicitis; however, the imaging studies were not available for review.

On physical examination, there was localized tenderness in the right upper quadrant, and Murphy's sign was positive. Laboratory investigations revealed a normal white blood cell count, and urinalysis was unremarkable.

Contrast-enhanced CT scan of the abdomen was performed to confirm the diagnosis. Representative images are shown in Figure 1. The CT scan demonstrated a dilated appendix measuring 1.3 cm in diameter with surrounding fat stranding, oriented superiorly with its tip abutting the inferior surface of the right hepatic lobe. The gallbladder wall was thickened to 0.4 cm, without intraluminal calculi or pericholecystic fluid. The kidneys, ureters, and urinary bladder were normal.

¹Department of Surgery, Philippine General Hospital, University of the Philippines Manila

²Division of Colorectal Surgery, Philippine General Hospital, University of the Philippines Manila

Based on these findings, a diagnosis of subhepatic appendicitis was established. The patient subsequently underwent laparoscopic appendectomy using a four-port technique (Figure 2): a 12-mm infraumbilical optical port, 5-mm ports in the left iliac fossa and left upper quadrant, and a 5-mm assist port in the right iliac fossa. The 5-mm assist port was inserted to facilitate retraction of the liver and gallbladder as the appendix was deep into the subhepatic space (Figure 3A).

Intraoperatively, a suppurative appendix was identified in an anterior position, with its tip extending into the subhepatic space (Figure 3B). The cecum was also situated subhepatically, superior to the right iliac fossa.

During the appendectomy, the patient was placed in the right-side-up, reverse Trendelenburg position. An energy device (LigaSure™, Medtronic, Dublin, Ireland) was used to dissect and ligate the mesoappendix and appendiceal artery. The appendiceal stump was secured with two extracorporeal Roeder’s knots.

The patient had an uneventful postoperative course. Good wound healing and recovery was seen during her follow-up on postoperative days 7 and 30. Histopathology revealed acute suppurative appendicitis.

Discussion

The position of the appendix is highly variable. It appears most commonly in the retrocecal (74%) area followed by the pelvic (21%), subcecal (1.5%), preileal (1%), and postileal (0.5%) positions.⁴ Atypical locations of the appendix include the subhepatic, left-sided, intraherniary, lumbar, and mesocolic.⁵

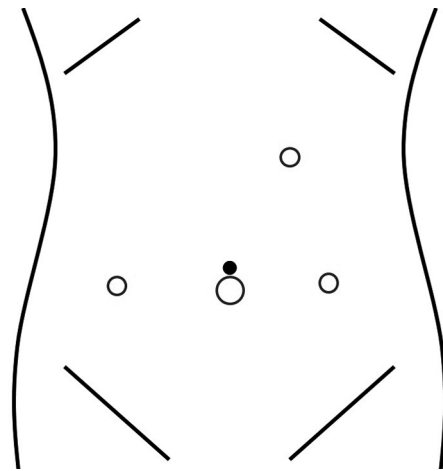


Figure 2. Diagram of trocar placement during surgery. (PGH, 2023)

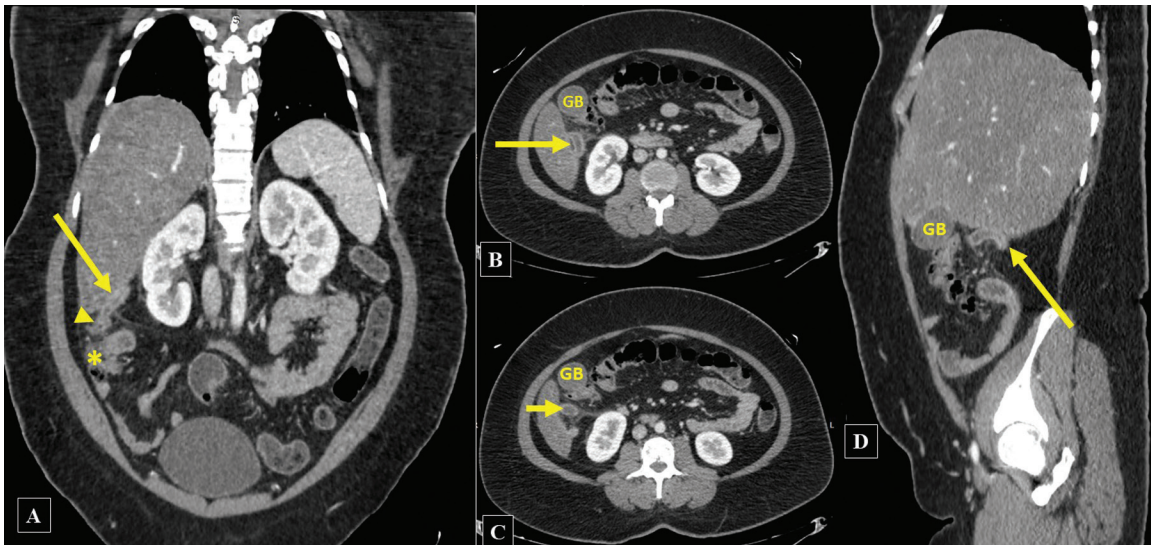


Figure 1. Contrast-enhanced abdominal CT scan (A) coronal oblique reconstruction showing a high-lying cecum (asterisk), the appendiceal base (arrowhead) and a dilated proximal appendix (arrow), coursing along the inferior margin of the liver, (B) axial view at the 2nd lumbar level showing the dilated subhepatic appendix (long arrow), (C) axial view at the 3rd lumbar level showing the appendiceal tip (short arrow) adjacent to the gallbladder (GB) fundus, (D) sagittal oblique reconstruction showing the appendix (long arrow) posterior to the gallbladder. PGH, 2023

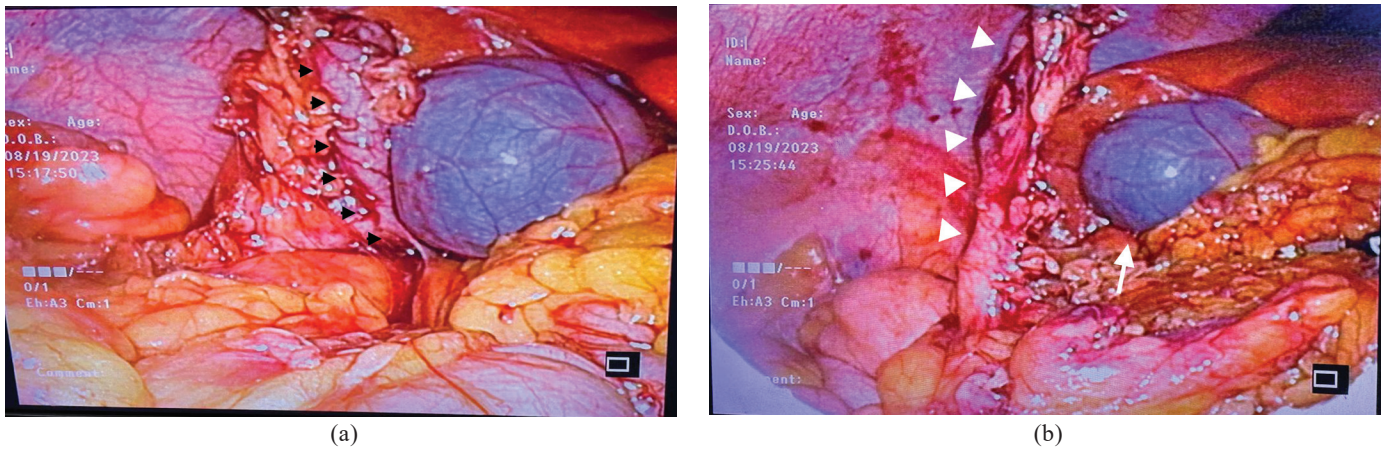


Figure 3. (a) and (b) Intraoperative photo showing the subhepatic location of the inflamed appendix (arrowheads). Note that the appendix is adjacent to the gallbladder (solid arrow). PGH, 2023

A subhepatic appendix is often the result of midgut malrotation or a failure of descent of the midgut.⁶ Subhepatic acute appendicitis due to an arrest of cecal descent was first reported by King in 1955.⁷ Since then, there have only been a few cases described in literature with more reports of malrotation rather than arrest in cecal descent as the cause of the anatomical variation.⁵ In this patient, malrotation was not seen on preoperative imaging and intraoperative evaluation, suggesting that isolated arrest of descent may be the underlying cause.

This case illustrates the diagnostic and therapeutic challenges posed by subhepatic appendicitis, particularly when it presents with clinical features suggestive of hepatobiliary disease. The aberrant location of the appendix alters the typical symptomatology of appendicitis and frequently leads to misdiagnosis or delayed intervention.

The clinical presentation of subhepatic appendicitis often deviates from the classical right lower quadrant pain, resulting in diagnostic challenges. Patients typically present with right upper quadrant pain, which may be mistaken for a hepatobiliary or gastric disease. Unlike classic appendicitis, nausea, vomiting, anorexia, and fever may be absent as illustrated in the present case. In contrast, acute cholecystitis frequently presents with right upper quadrant pain accompanied by fever, leukocytosis, and a positive Murphy's sign, findings also present in this patient, further confounding diagnosis.

These overlaps emphasize the need for a high index of suspicion for subhepatic appendicitis in atypical right upper quadrant presentations. Physical examination alone may be misleading. Although right upper quadrant tenderness and a positive Murphy's sign are commonly associated with cholecystitis, they can also be elicited in subhepatic appendicitis when the inflamed appendix lies adjacent to the liver capsule. Therefore, clinical examination alone is insufficient in distinguishing these entities.

Given this diagnostic dilemma, imaging plays an important role. Ultrasonography is often the first modality performed due to accessibility, however, this has a high probability of misdiagnosis in these cases because the appendix may be obscured by bowel gas or misinterpreted as other structures.⁸ In a systematic review of Shivalingam Vanaraj et al., ultrasonography identified subhepatic appendicitis in roughly 25% of cases.⁹

Contrast-enhanced computed tomography (CT) is the imaging modality of choice for suspected subhepatic appendicitis. It allows reliable visualization of the appendix regardless of anatomical location and can differentiate appendicitis from hepatobiliary and gastric pathology. Sensitivity has been reported between 88-100% and specificity between 92-98% for appendicitis overall, with similar diagnostic performance when identifying appendicitis in atypical positions. The high

negative predictive value (95–100%) further supports its use in excluding appendicitis when clinical suspicion persists despite atypical signs.¹⁰ In the patient of the present case, CT scan clearly demonstrated a dilated appendix with periappendiceal fat stranding in the subhepatic space, hence, demonstrating a conclusive diagnosis.

Shivalingam Vanaraj et al. comprehensively reviewed the reported cases of subhepatic appendicitis. The majority of documented patients (71%) were adults, with a male predominance (68%). Abdominal pain was most commonly localized to the right upper quadrant (82%), and abdominal tenderness was present in 91% of cases. Ultrasonography was performed in nearly 90% of patients; however, subhepatic appendicitis was correctly diagnosed in only 27% of these cases. In contrast, CT scan confirmed the diagnosis in up to 81% of patients. Almost all patients (96%) underwent surgical intervention, with laparoscopic appendectomy performed in 52% of cases. The conversion rate to open surgery was 16%. Approximately 30% of surgically managed patients had complicated appendicitis. More than half (58%) had associated congenital anomalies, including an undescended or subhepatic cecum, intestinal malrotation, or a short ascending colon. Notably, over 98% of patients experienced an uneventful recovery.⁹

Management strategies must be tailored to the individual patient. There is no universally accepted guideline for subhepatic appendicitis due to its rarity.¹¹ Laparoscopy is preferred in stable patients without diffuse peritonitis, allowing comprehensive intraabdominal evaluation with minimal morbidity. Success in laparoscopic management requires a tailored approach, altering standard port positions, even placement of an additional port, to aid with optimal operative access.²

Conclusion

Subhepatic appendicitis is a rare but clinically significant cause of right upper quadrant abdominal pain that may mimic hepatobiliary or gastric pathology. Due to its atypical presentation, diagnosis based solely

on clinical findings is often challenging. Contrast-enhanced computed tomography remains the most reliable diagnostic modality for identifying appendicitis in aberrant anatomical locations. Once diagnosed, laparoscopic appendectomy can be performed safely and effectively using a tailored approach to port placement, allowing optimal visualization and reduced morbidity. Early recognition and appropriate surgical management are essential to prevent diagnostic delay and ensure favorable patient outcomes.

References

1. Dixon F, Singh A. Acute appendicitis. *Surgery (Oxford)* 2020;38(6):310-7. doi:10.1016/j.mpsur.2020.03.015
2. Palanivelu C, Rangarajan M, John SJ, Senthilkumar R, Madhankumar MV. Laparoscopic appendectomy for appendicitis in uncommon situations: the advantages of a tailored approach. *Singapore Med J* 2007;48(8):737-40.
3. Ball WB, Privitera A. Subhepatic appendicitis: A diagnostic dilemma. *BMJ Case Rep* 2013;2013:bcr2013009454. doi: 10.1136/bcr-2013-009454.
4. Hakim M, Mostafa R, Al Shehri M, Sharawy S. Surgical management of subhepatic perforated appendix: A case report. *J Med Case Rep* 2020;14:151. doi:10.1186/s13256-020-02499-2
5. Evola G, Lanaia A, Cantella R, Di Fidio C, Di Fede GF, Piazza L. Subhepatic perforated acute appendicitis in a patient with midgut malrotation: A case report and review of literature. *Int J Surg Case Rep* 2022;95:107249. doi:10.1016/j.ijscr.2022.107249
6. Ashwini E, Varun M, Saravanan PS, Julian S, Sandeep P. Hidden appendix: A case report and literature review of perforated acute appendicitis masquerading as acute cholecystitis. *Int J Surg Case Rep* 2022;97:107480. doi:10.1016/j.ijscr.2022.107480
7. King A. Subhepatic appendicitis. *AMA Arch Surg* 1955; 71(2):265-7. doi:10.1001/archsurg.1955.0127014011302
8. Alqatani S, Lasheen M, Paray S. Subhepatic appendicitis in an 11-year-old boy: A case report. *Cureus* 2019;11(12):e6489. doi:10.7759/cureus.6489
9. Shivalingam Vanaraj NA, Vishwajit GV, Vijayakumar K, Senthilkumar V, Dharapuram Srinivasan M. Subhepatic appendicitis: A systematic review of clinical presentation, diagnostic challenges, and surgical management. *Cureus* 2025 Nov 28;17(11):e98002. doi: 10.7759/cureus.98002.
10. Leite N, Pereira J, Cunha R, Pinto P, Sirlin C. CT evaluation of appendicitis and its complications: Imaging techniques and key diagnostic findings. *Am J Roentgenol* 2005;185(2):406-17. doi:10.2214/ajr.185.2.01850406
11. Yousef A, Suleimanov V. Subhepatic appendicitis presenting with recurrent abdominal pain. *Cureus* 2022;14(12):e32939. doi:10.7759/cureus.32939